



**PATIENT**

Finnegan Di Lorenzo

**SPECIES**

Feline

**BREED**

DSH

**SEX**

Male Neutered

**AGE**

14 years

**WEIGHT**

10.7lbs

**INTERPRETED BY**

Maggie Machen Lamy,  
 DVM DACVIM  
 (Cardiology)

**IMAGING PERFORMED BY**

Kelly Reschny, RVT

**HOSPITAL NAME**

East Credit VH

**REFERRING VET**

Dr. Webster

**INVOICE**

46169

**DATE**

12/12/25

**PRESENTING CLINICAL SIGNS**

History: Recheck echo – previously evaluations have been normal with no cause for a murmur identified. Sedated with Alfaxalone.

**ECHOCARDIOGRAM FINDINGS**

2D, m-mode, color flow and doppler imaging is available. The left ventricular wall is normal in dimension. There is a mildly hyperechoic endocardium. The papillary muscles are mildly remodeled and hyperechoic. The left atrium is normal in size. The right atrium is normal in size. The right ventricle appears normal. The mitral valve is normal in structure and mobility. Blood flow through both the LVOT and RVOT is normal in velocity. No obvious congenital defects. No pleural or pericardial effusion seen. No obvious cardiac tumors.

**CARDIAC CHART**

FELINE CARDIAC PARAMETERS	BODY WEIGHT (kg)	HR (BPM)	IVSd (cm) (Moise, Pipers)	LVIDd (cm) (Moise, Pipers)	LVWd (cm) (Moise, Pipers)	FS (%)	EF (%)
NORMAL PARAMETER	-----	150-240	0.35-0.55	<2 (mean 1.5)	3.5-0.55	35-67	80-100
PATIENT	4.9	120	0.40	1.4	0.39	52	80
FELINE CARDIAC PARAMETERS	LA/AO (Boon)	LA/AO HEART BASE (Swe) (Abbott)	LA 2D short axis Base view (cm) (Abbott)		LVOT VEL (m/s)	RVOT VEL (m/s)	E max (m/s)
NORMAL	<1.5	<1.3	<1.2		<1.6	<1.3	<0.9
PATIENT	1.2	1.2	1.10		0.9	0.8	NM

*\*Note: All measurements based upon multi-modal images and methods. An average value is reported.  
 Adapted from June Boon, Veterinary Echocardiography, 1998  
 Abbott J & MacLean H JVIM 2006;20: 111-119, Moise et al. Am J Vet Res 47:1476, 1986. Pipers et al. Am J Vet Res 40:882, 1979.*

**INTERPRETATION OF THE FINDINGS & FURTHER RECOMMENDATIONS**

Normal findings persist, with no LV hypertrophy or significant valve regurgitation. No cause for the murmur is identified.

Given these findings, no medications are indicated. Prognosis is open.

No cardiac contraindication for general anesthesia.

Recommend recheck echocardiogram annually, sooner if clinical signs arise.



**PATIENT**

Finnegan Di Lorenzo

**SPECIES**

Feline

**BREED**

DSH

**SEX**

Male Neutered

**AGE**

14 years

**WEIGHT**

10.7lbs

**INTERPRETED BY**

Maggie Machen Lamy,  
DVM DACVIM  
(Cardiology)

**IMAGING PERFORMED BY**

Kelly Reschny, RVT

**HOSPITAL NAME**

East Credit VH

**REFERRING VET**

Dr. Webster

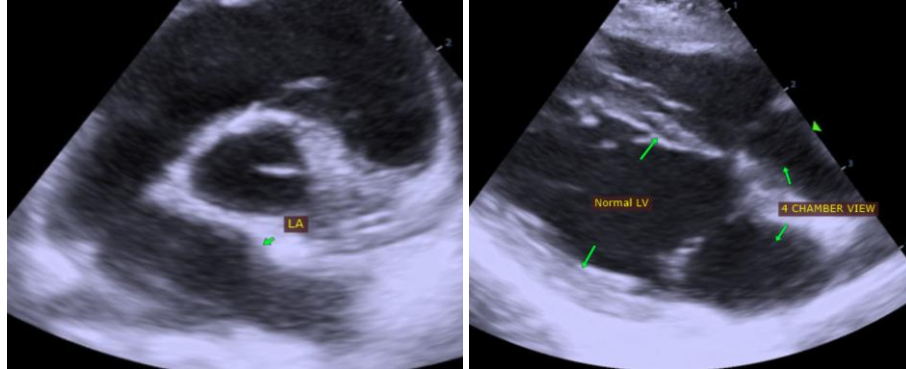
**INVOICE**

46169

**DATE**

12/12/25

**IMAGES**



The information and recommendations provided are based on the images presented by the referring veterinarian. No evaluation can be communicated regarding pathology that was not visible in the image/video clips provided.

Thank you for this referral. This report was generated using transcription software, and minor dictation errors may be present. If the clinical or image interpretation does not parallel your findings or if I can be of any further assistance, please contact me.

**Maggie Machen Lamy, DVM**  
Diplomate of the American College of Veterinary Internal Medicine (Cardiology)  
info@sonopath.com